



WP

BBD

YBD & BBD

YBD

DSD

WBD

Field Guide
to
WESTERN ATLANTIC
CORAL DISEASES

WPD

UWS

bleaching

GAs



Photos and text: Andrew Bruckner, 2009

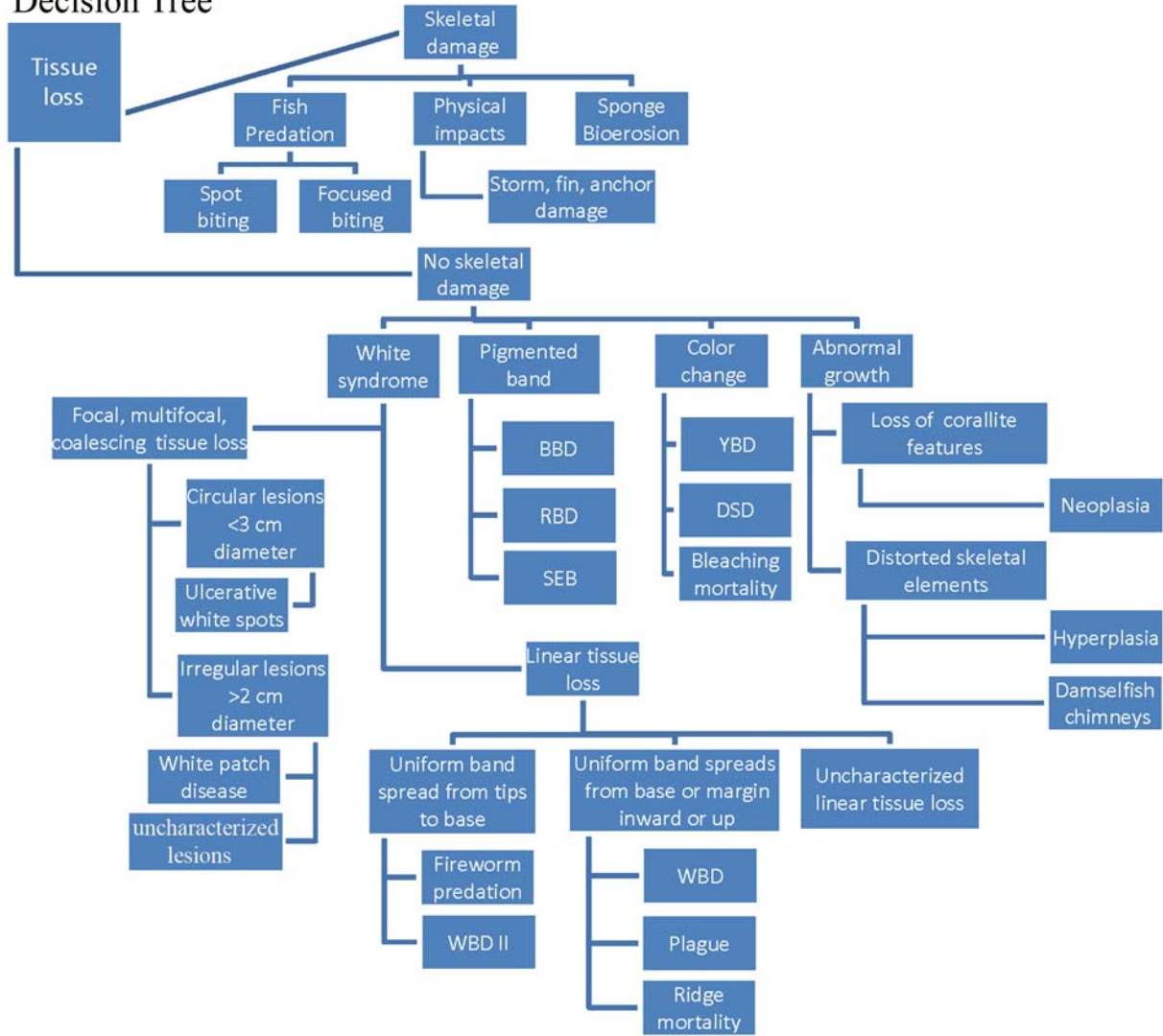
Western Atlantic Coral Disease Identification Field Guide uses standardized nomenclature and diagnostic criteria for coral diseases developed by the Coral Disease and Health Consortium (CDHC). This involves a three-tiered approach to naming diseases and a decision tree that would help unify disease names. Through application of a series of steps, a researcher can determine a common field name for a disease which can be further refined based on a morphologic diagnosis and an etiologic diagnosis. This is based on techniques applied to the study of other terrestrial and marine animal diseases that include 1) detection of disease, 2) description of the morphologic changes in the host associated with the disease, 3) evaluation of morphologic changes in the host as disease progresses (e.g., *pathogenesis*), determining the cause (e.g., *etiology*), and physiologic changes in the host as the disease progresses (e.g., *pathophysiology*). These underwater cards help a diver complete a level 1 diagnosis.

Level 1: Categorization of obvious gross field signs directly visible to the diver without magnification or sampling. The first step involves the identification of four easily observed descriptive categories – presence of color change, tissue loss, skeletal damage and irregular growth. The observer also records other gross visible signs such as the location and distribution of the lesion, condition of the affected tissue, and the extent of tissue loss. Based on an analysis of these characters, it is possible to identify a common field name to describe the disease in the particular coral and apply the same terminology to other corals (regardless of species) with similar gross visible signs. This approach is used primarily for rapid assessment and routine monitoring.

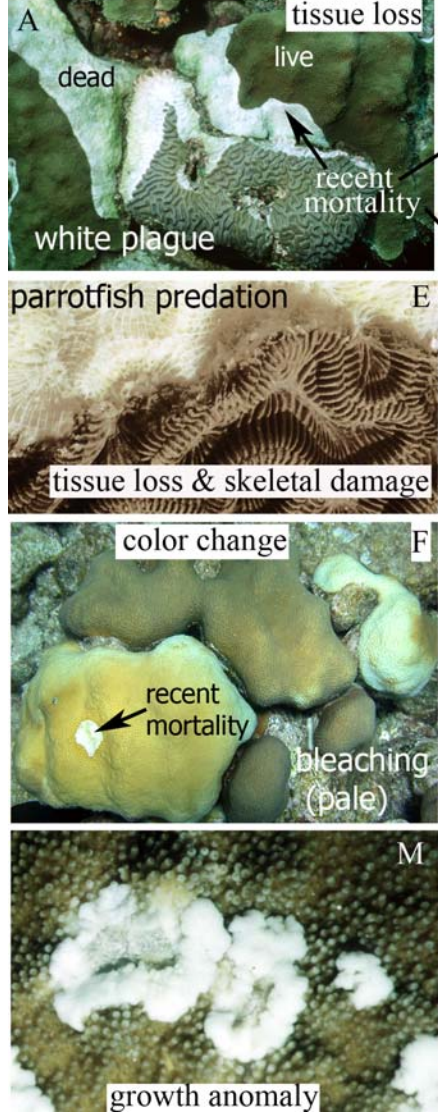
Level II: Detailed examination of affected and unaffected tissue taken from the diseased coral (and compared to representative presumed healthy corals) using histology. This approach can help identify the presence of microorganisms and describe morphological changes to the tissue. This could result in a morphologic diagnosis.

Level III. A detailed set of field and laboratory tests to identify and confirm the presence of proposed causative agent (s), toxin, or other factor responsible for the manifestation of the disease. Microbial diseases may be determined according to Koch's postulate – where a presumed pathogen is isolated, grown in pure culture, identified, and used to infect a presumably healthy host. If the disease signs appear, and the presence of the presumed pathogen is confirmed, and an etiologic diagnosis can be assigned.

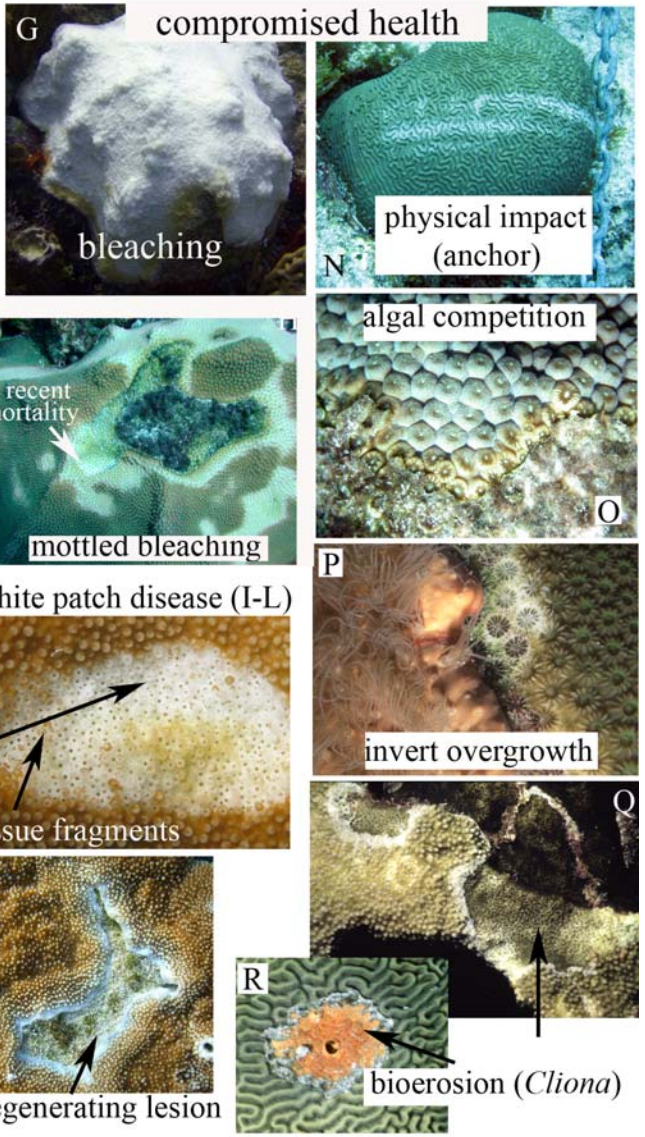
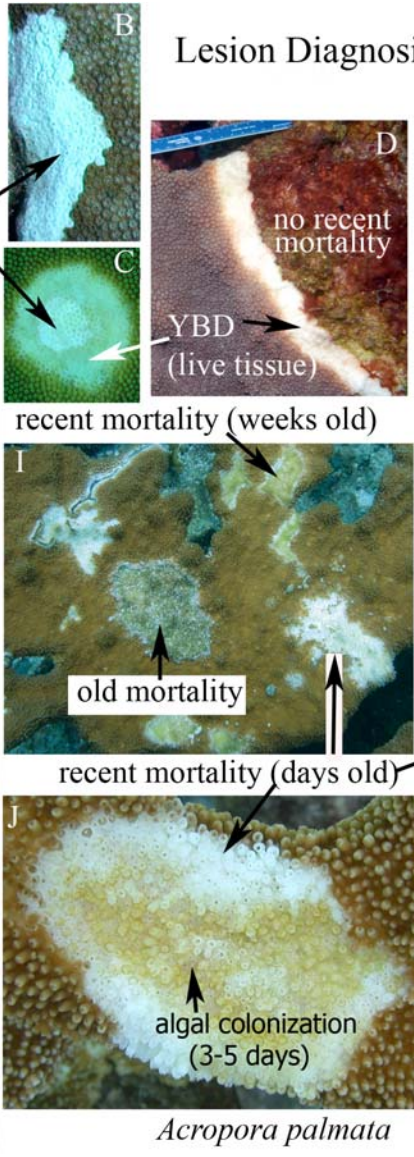
Decision Tree



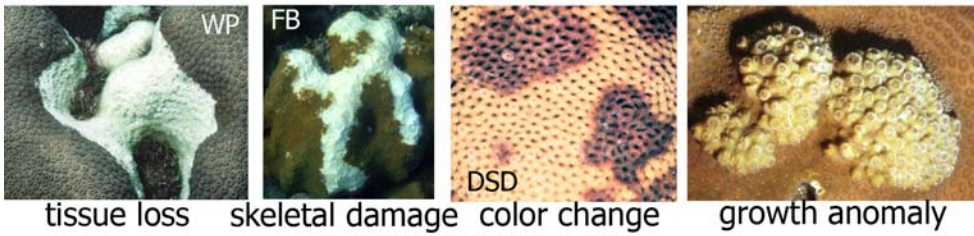
Level I Diagnosis



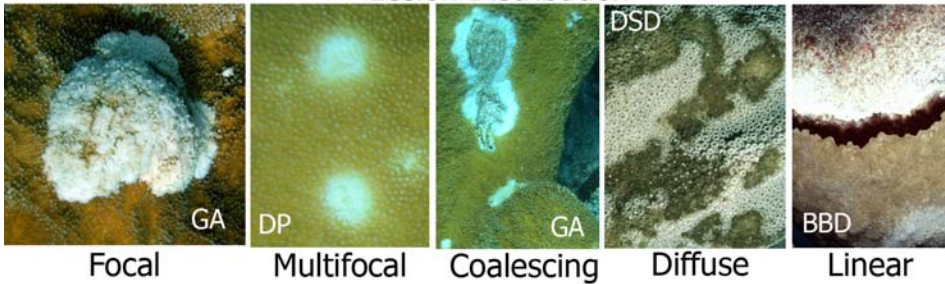
Lesion Diagnosis



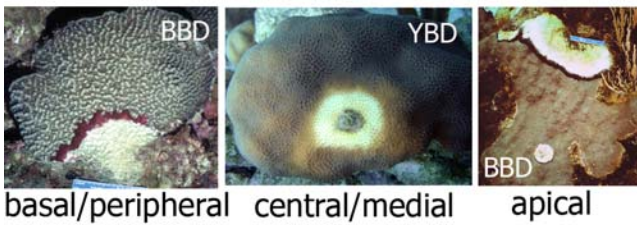
LESION DESCRIPTIONS



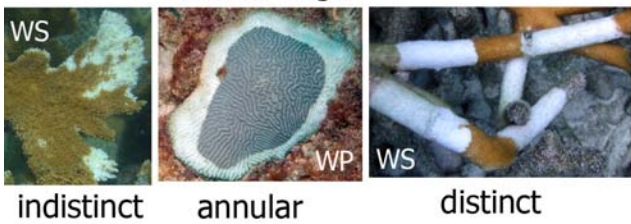
Lesion Distribution



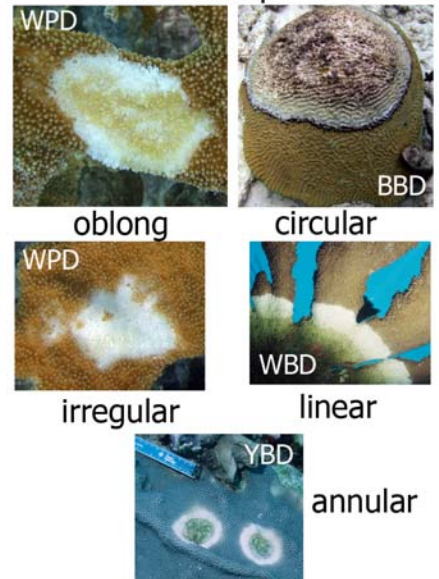
Lesion Location



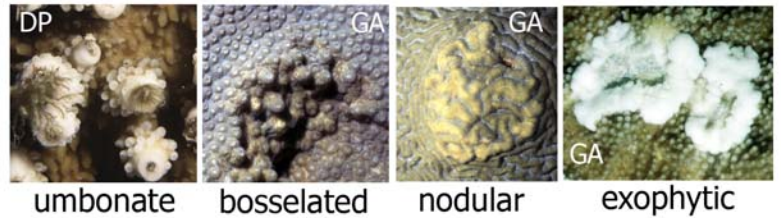
Lesion Edges




Lesion Shape



Lesion Relief



Lesion Margin



Acropora white syndromes. Lesions on elkhorn coral (*Acropora palmata*) and staghorn coral (*A. cervicornis*) characterized by recent tissue loss separating live tissue and algal-colonized skeleton; no evidence of color change; absence of a pigmented band, no skeletal damage or abnormal growth. Lesions may be focal, multifocal, coalescing, linear or annular. The lesion location, shape and pattern of spread are unique for each syndrome. Snails or fireworms may occur on lesions and they also cause similar patterns of tissue loss.

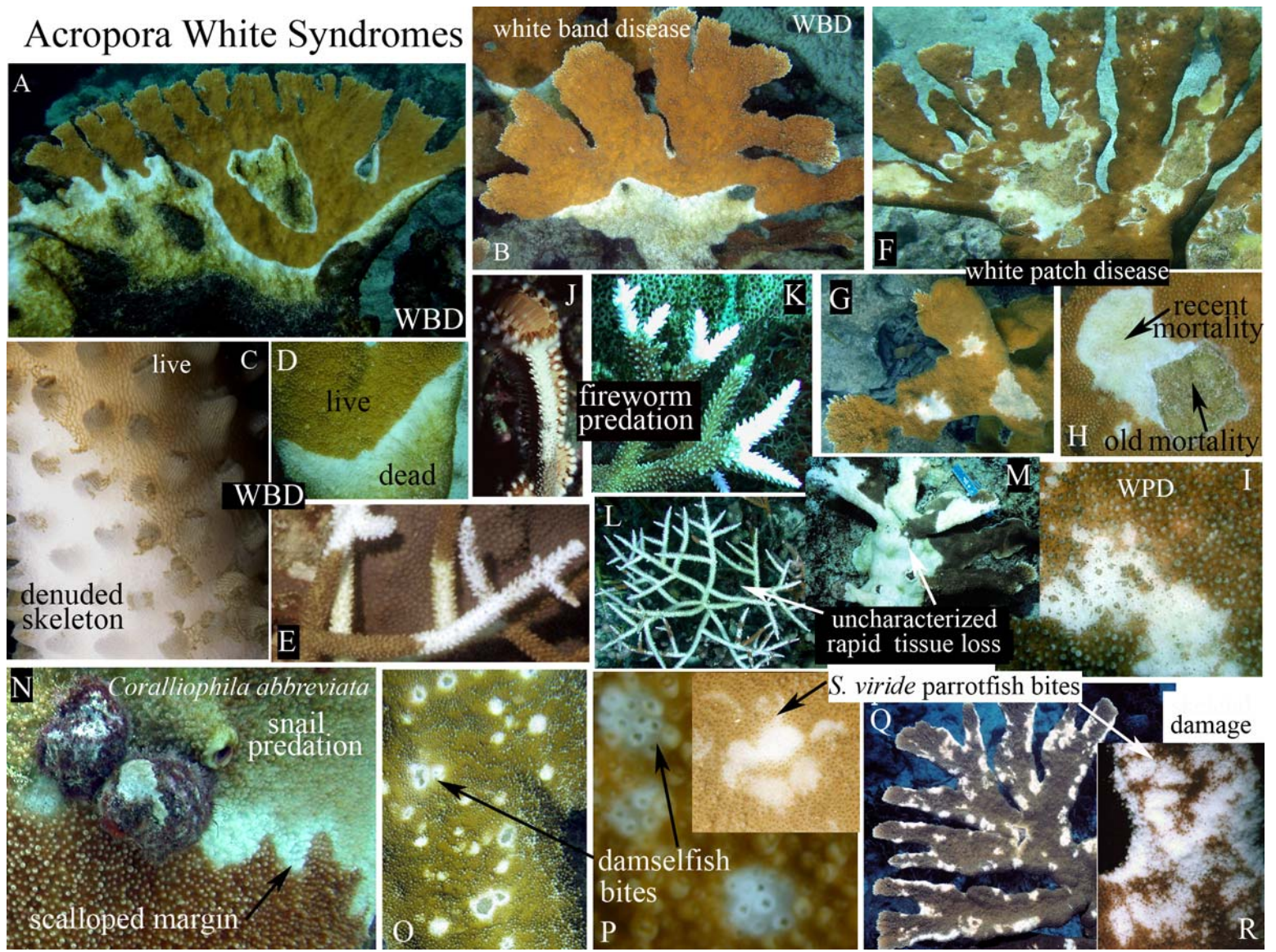
White band disease (WBD) (A-E): Lesions may be annular or linear, spreading from the base to the tips, or starting at a branch bifurcation and spreading up or down; tissue loss advances 1-100 mm/day. On *A. palmata* tissue loss may progress up the underside or upper surface of the branch; the band also may encircle the entire branch. Tissue at the lesion margin may be bleached (WBD type II) and small pieces of tissue may be peeling off the skeleton (C) Exposed skeleton is progressively colonized by epibionts.

White patch disease (WPD) (F-I), also called patchy necrosis, white pox. Irregular, focal to multifocal, coalescing lesions, irregular in shape, completely surrounded by living tissue. Lesions initiate within a branch surface on unaffected tissue (I) or at the margin of an old lesion (H) Colonies may have acute (recent), subacute (colonized) and old lesions (F) lesions radiate out over time and coalesce; resheeting occurs once mortality stops. Lesions have a sharply demarcated leading edge of tissue loss; tissue remnants may be present and corallites may be broken. 1-80 cm in diameter, Damselfish may be associated with WPD lesions and may cause similar patterns of tissue loss.

Uncharacterized rapid tissue loss (L,M). White syndromes with diffuse, rapid tissue loss in an irregular pattern that differs from WBD and WPD.

Similar conditions: Fireworm predation (J-K) resembles WBD type II; tissue loss confined to branch tips. Recent lesions lack algal colonization; tissue margin is smooth and not sloughing **Snail predation(N)** advances in a linear or annular pattern like WBD, but lesions have a serpiginous scalloped or undulating margin the shape of the snail's shell; snails are on the lesion or at the colony perimeter. **Damselfish bites (O-P):** round to irregular, focal, multifocal or coalescing, small (1-3 cm) but expanding lesions often with broken corallites; may form "chimneys". **Parrotfish predation (Q-R):** irregular loss of tissue and underlying skeleton often at the edge of the branch; scrape marks and jaw pattern may be visible.

Acropora White Syndromes



White Syndromes: Massive, plating and branching corals. Non-acroporids.


DIAGNOSTICS: Focal, multifocal and coalescing lesions with a linear margin. Linear or annular tissue loss initiating at the base or perimeter of a colony, or from the margin of an old lesion and progressing as a front 1 mm to 10 cm/day. No distinctive pigmented band or mat, tissue discoloration, or skeletal damage. Snails and fireworms may be present.

White plague (WP): A distinct band of white, tissue-denuded skeleton separates healthy tissue from algal-colonized skeleton. May initiate at the colony margin (**A-B**) or from a previously killed portion of a colony (**C**) and radiate out in an irregular to annular pattern (**D**). A narrow band of white skeleton adjacent to colonized skeleton is indicative of slow spread (**E, F, L**; “Type I”) while a large band up to 10 cm or more in width indicates rapid spread (**G,K,I,O**; “Type II”). Lesion margin may be irregular (**H**), serpiginous (**M**), or annular (**I, J, O**). Individual portions of the band may advance at different rates. WP advances from one coral to adjacent colonies. Affects at least 42 species of corals.

White syndrome (WS): Uncharacterized lesions with diffuse patterns of tissue loss; focal, multifocal coalescing; may have linear, or annular margins, with a sharp demarcation between normal tissue and bare skeleton. Irregular lesions on *Agaricia* (**G**) are shown.

Similar conditions: Damselfish lesions. Fish territories occur among corals; bite marks denude tissue in a focal or multifocal pattern (**N**). Lesions may progressively expand in annular manner, and new lesions appear in other locations. **Snail predation:** aggregates of snails may remove tissue in a focal or annular pattern; snails may be on the lesion or at the perimeter of the colony. **Parrotfish predation** may result in multiple small focal or multifocal lesions and larger annular bands that progressively expand in size; these have tissue loss and skeletal damage. **Bleaching-associated mortality:** may appear as discrete focal, multifocal and coalescing lesions near pale to white tissue.

White Syndromes (massive/plating corals)



Pigmented Band Diseases

Black band disease (A-I) Black or dark reddish-brown band or mat of filamentous organisms (A), peppered with white filaments (B), 1-30 mm wide, radiating out 1-20 mm/day (C-D). The band may be linear to annular (E-F) to irregular. It initiates at the colony margin or base (C) or a focal site of injury (G); in brain corals often starts at the top and spreads down (H). The band separates healthy tissue and stark white tissue-depleted skeleton. Secondary colonization of denuded skeleton by filamentous algae followed by other epibionts (H). Affects 22 scleractinian corals, 1 hydrozoan coral and four octocorals.

Red band disease (K-O) Thin red band of filamentous cyanobacteria loosely associated with the coral, separating tissue and white skeleton; filaments are less mat-like and do not contain white filaments (N) A second variety consists of a mat that expands in day over tissue and skeleton and forms a discrete band at lesion margin at night (O) **Similar conditions:** BBD and RBD may be difficult to distinguish; cyanobacteria may also form a mat on the surface of corals (L,O) that migrates diurnally and can kill tissue; Mostly on *Colpophyllia*, *Agaricia*, *Meandrina*.

Caribbean ciliate infection (P-T) A diffuse black or grey band, several mm up to 1-2 cm thick, with a “salt-and-pepper” speckled appearance, separating living tissue from algal colonized skeleton. May form a discrete, dark band several mm thick (acute infection) or diffuse, scattered patches on algal colonized skeleton. Ciliates visible with hand lens. May occur on colonies with white plague or WBD. Affects *Montastraea*, *Acropora* (Q-S), *Diploria* (T), *Dichocoenia*, *Agaricia* (22 species) .

Similar conditions: CCI can be confused with BBD, DSD, and denuded skeleton colonized by epibionts.

PIGMENTED BAND DISEASES (BBD, RBD, CCI)

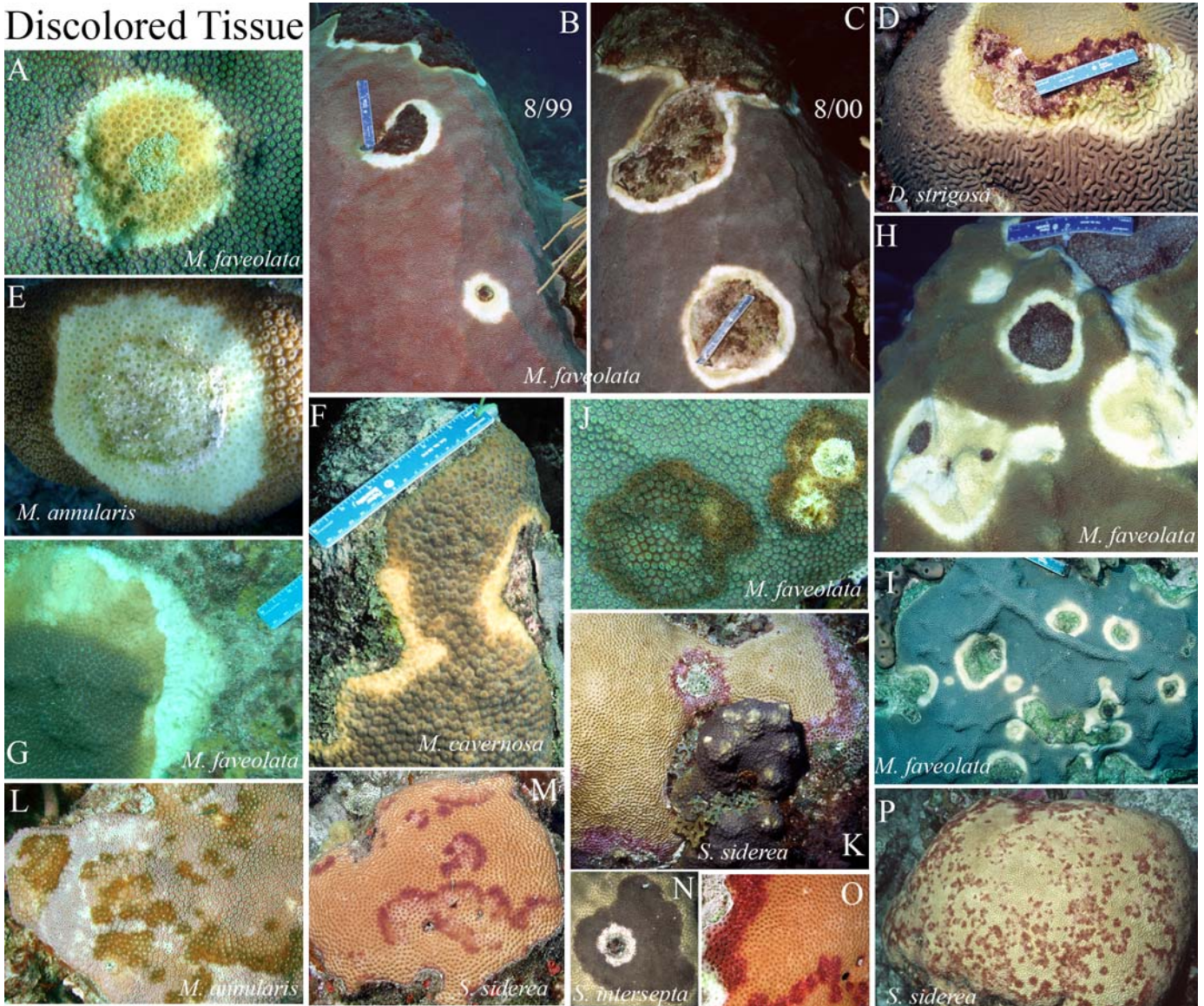


Discolored Tissue

Yellow band disease, YBD (A-I) Begins as a pale yellow, circular blotch of tissue surrounded by normal tissue (A), or as a narrow band at the edge of a colony (F). These focal (E), multifocal (I) or annular to linear lesions expand in size a few mm to cm per month, coalesce (H) and slowly migrate across the colony (B-C). The leading edge of the band becomes a light pale yellow or lemon color, while tissue first affected gradually darkens prior to dying (A). Small patches (< 1cm) of recent tissue loss may be observed, but skeletal areas are usually colonized by epibionts (G). May be confused with bleaching. Most common in *Montastraea annularis* (E) and *M. faveolata* (A,B,C, H, I) also in *Diploria strigosa* (D), *M. cavernosa* (F) and other faviids.

Dark spots disease, DSD (J-P) Round to irregular, focal to multifocal, dark spots, purple to brown in color, 1-45 cm or more in diameter. Dark spots may grow in size over time, coalesce (J, L), and form irregular to annular bands (M) adjacent to or surrounding exposed skeleton. Affected tissue may be associated with a depression of the coral surface (N) and in some cases spots may appear seasonally. In *Siderastrea*, purple spots may appear over the surface, or form a band at the edge or within the coral that slowly moves (M,O); Tissue loss is generally very slow. The underlying skeleton often retains the dark pigmentation when exposed. Most common in *Siderastrea* (K,M,O,P), *Montastraea* (I, L) and *Stephanocoenia* (N).

Discolored Tissue



Discolored tissue and bleaching

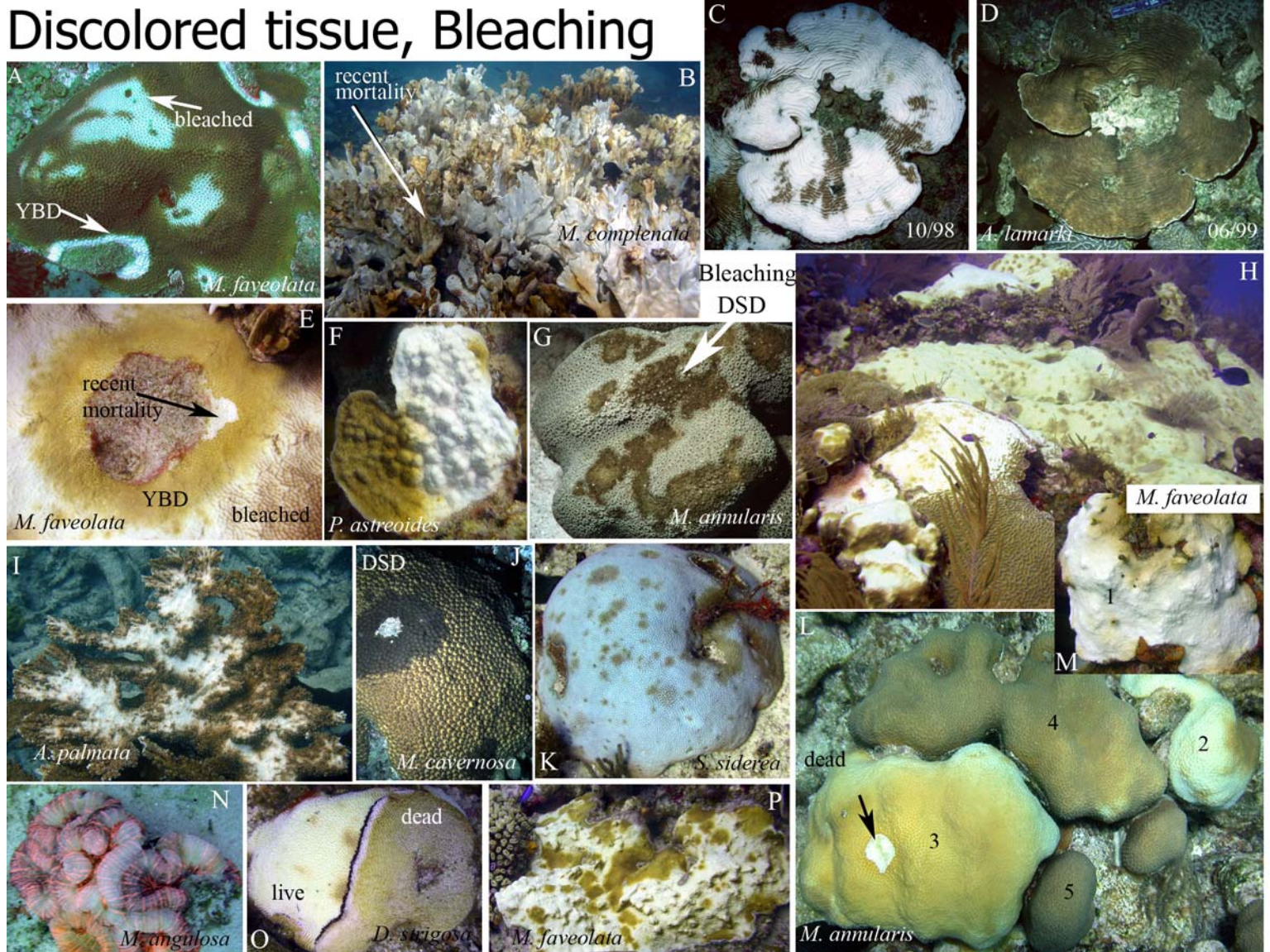
Similar conditions: Bleaching can be misidentified as: 1) **yellow band disease** (YBD) lesions which are pale yellow bands blotches surrounded by fully pigmented tissue. On a bleached coral, the YBD is usually darker than surrounding tissue (**E**). YBD can also be similar in color to bleached patches (**A**). 2) Large white bands of recent tissue loss from WP appear bleached, but lack tissue and have visible skeletal elements. 3) **dark spots disease** (DSD) dark spots or bands at the margin or within the tissue(**G, J**).

Bleaching affects the entire colony (**B, C, H**), upper surfaces (**F**), the base, or focal to multifocal patches (**I,P**). Coloration may vary from pale to white within individual species (**L-N**); white irregular patches of tissue loss may occur near bleached areas (**L**). Corals that bleach (**C**) may recover (**D**). **A scale of bleaching from 1-5 can be used: 1= white; 2= light yellow; 3=yellow; 4= light brown; 5= normal.**

Severity of bleaching can range from: **pale:** colonies that are lighter than normal; **partially bleached:** the loss of some or all color in a random mosaic pattern; **mostly bleached:** colonies that are uniformly pale yellow to off white; and **fully bleached:** colonies that appear uniformly white and the skeleton is seen through translucent coral tissue; Other patterns of bleaching also occur including **ring bleaching:** rings of pale or white tissue up to 4 cm in diameter and 2-5 mm in width, each with a center of unbleached tissue.

Bleached colonies may exhibit a distinct blue (**K**), yellow, green, or reddish (**N**) fluorescence. Corals that bleach may be more susceptible to other diseases such as BBD (**O**).

Discolored tissue, Bleaching



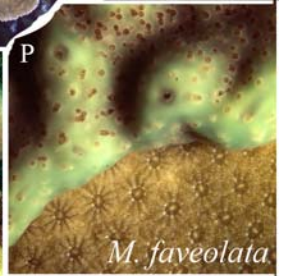

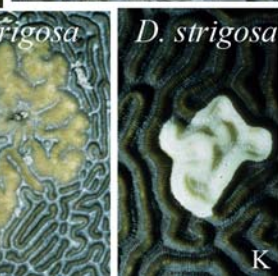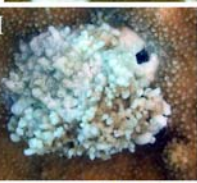

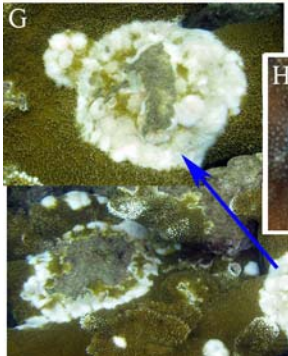
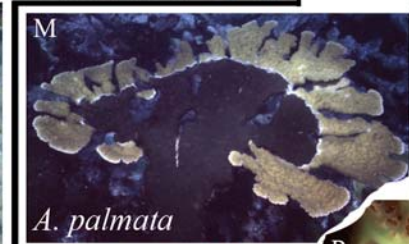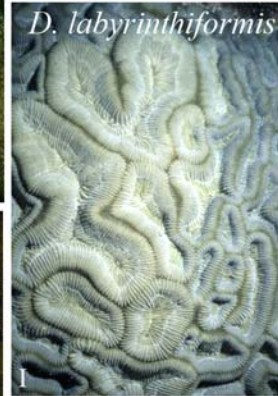
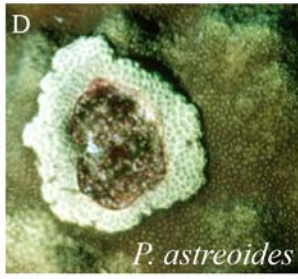
Growth anomalies and overgrowth/competition by algae, sponge, tunicate, or cnidarian

Growth Anomalies (GAs): coral skeletal anomalies resulting from abnormal development of skeleton and associated tissue. Deposition of exoskeleton is altered and morphological features differ markedly from those of the surrounding skeleton and tissue in shape, presence of polyps, size of tissue and skeletal elements, color of tissue, and rate of growth. Can develop on any region of the colony, lesions expand outward and may coalesce. Up to 20-cm in diameter.


1. **Enlarged structural elements (A-C, K)**, also referred to as gigantism, area of accelerated growth, hyperplasm. Focal or multifocal circular to irregularly shaped lesion; abnormally arranged skeletal elements (calices, ridges, valleys), which are larger or smaller than those of the adjacent colony surface. Intact normal-appearing tissue, similar in coloration to adjacent tissue. Often protrudes above the surface of adjacent tissue
2. **Loss of normal structural elements (D-H)** also called tumor, neoplasm, calicoblastic epithelioma. Focal or multifocal circular to irregularly shaped protuberant lesion consisting of coenosteal skeleton development between and over normal calices, with corresponding loss of polyps. Usually covered by intact tissue lacking zooxanthellae “Bubbling” of tissue may occur at margin of lesion.
3. **Chaotic polyp development (H-J)** Focal or multifocal spherical to irregularly shaped protuberant lesion consisting of abnormally arranged calices and coenosteum. Usually covered by intact normal-appearing tissue, similar in coloration (sometimes lighter or darker, but zooxanthellae present) to adjacent tissue.

Overgrowth and competition. Presence of sponge (**L-M**), encrusting gorgonian (**N**), tunicate (**O-P**), hydrozoan coral (**Q**), algae (**R**) or other epibiont on colony surface and progressively overgrowing tissue; may be associated with bioerosion of skeleton (**L-M**).

Growth Anomalies



Overgrowth



Predation & corallivory. Snails (A-D), fireworms, parrotfish and damselfish cause visible lesions

Similar conditions: Predation can be confused with white band disease, white plague and white patch disease.

INVERTEBRATE PREDATION: Check for the presence of corallivores at the lesion margin or the base of the colony. *Hermodice* fireworms (F) engulf entire branches and protuberances on the colony; uniform and complete removal of tissue from branch tips or projections; smooth, uniform margin between skeleton and live tissue; no evidence of tissue sloughing. Feed mostly at night.


Coralliophila snails (A-E) feed in groups (2-70+) at the edge or base of a coral consuming tissue directly under their shell footprint, creating a scalloped pattern. Tissue loss initiating at base or perimeter of coral. The feeding scar progressively radiates out in a linear or annular pattern, but it may extend in an irregular path across the coral. Tissue loss is concentrated on upper surfaces of branches (B) Lesion margin may be irregular, serpiginous, serrated or undulating (A); no sloughing of tissue at the interface of exposed skeleton like in WBD, WP and WPD.

FISH PREDATION: Fish may be seen biting coral; fresh lesions stream mucus. Absence of tissue and skeleton.

Parrotfish predation. 1) spot biting (M-P): Focal and multifocal scrapes and pairs of bite marks, each <2 cm elongate, concentric or irregular in shape; acute lesions and recovering lesions (P) may occur together **2) focused biting (Q-T):** loss of larger areas of tissue and skeleton to depths of 1-2 cm; removal of entire knobs, projections, branch tips (R), and edges of plates; focal, multifocal, coalescing and linear lesions 2-50 cm diameter; lesions expand from the perimeter across exposed surfaces (S); tissue in depressions/ bases often undamaged (Q).

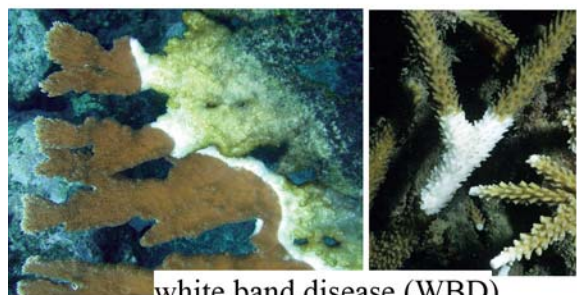
Damselfish predation . 1. Lesions on *Acropora* are circular to irregular (<2 cm in diameter) and may occur over the entire branch; accelerated calcification may result in chimney-like structures (G-H). Lesions may also become larger, resembling white patch disease; no skeletal damage but corallites often broken **2.** *S. planifrons* bite on the projecting ridges of **brain corals (J-L)** removing tissue from one or more ridges. As ridges are colonized by algae, fish bite new areas causing the lesion to radiate out in a linear or annular manner. Also called Ridge Mortality. On faviids, fish bite individual round corallites which will appear white, often with a tuft of filamentous algae (I).

Predation (snail, fireworm, damselfish, parrotfish)




Disease	Diagnostics	Description
White band disease (WBD)	Distinct, linear band of recent tissue loss Separating healthy tissue from exposed, algal colonized skeleton	Tissue loss, absence of pigmented band or mat at the lesion border. WBD typically starts at the colony base or at branch bifurcations, advancing upward 1-100 mm/day. Exposed skeleton is progressively colonized by epibionts; WBD may advance up the underside of the colony or only the top surface The band sometimes encircles the entire branch. Tissue adjacent to lesion may be bleached. Snails and fireworms often occur at the disease front; they also may cause similar patterns of tissue loss. Affects acroporids
White patch (WPD)	Irregular, focal or multifocal lesions, surrounded by normal tissue	Lesions have a sharply demarcated leading edge of tissue loss; tissue remnants may be present near the leading edge and corallites may be broken. Lesions may radiate out over time and coalesce, or begin resheeting once mortality stops. 1-80 cm in diameter, Damselfish may cause similar lesions. Affects acroporids
White plague (WP)	Focal, multifocal and coalescing lesions with a linear or annular margin	Linear tissue loss; progresses in a band-like pattern, initiating at the base or perimeter of a colony, or from the margin of an old lesion advancing 1 mm to 10 cm/day. A distinct band of white, tissue-denuded skeleton separates healthy tissue from algal-colonized skeleton. No distinctive pigmented band or mat; affects 42 species.
White syndrome (WS)	Irregular, focal to annular tissue loss	Uncharacterized lesions with diffuse patterns of tissue loss; focal, multifocal coalescing; may have linear, or annular margins, with a sharp demarcation between normal tissue and bare skeleton.
Black band disease (BBD)	Linear or annular pigmented band separates live tissue and white skeleton	Crescent shaped or circular band or mat of filamentous organisms, Black to reddish-brown and often mixed with white filaments, separating live tissue from white exposed coral skeleton. The black band is <1-20 cm wide; width and rates of spread vary over the duration of BBD. Mostly affects <i>Montastraea</i> and <i>Diploria</i> spp.; 17 other spp.
Red band (RBD)	Linear or annular pigmented band	Narrow band of red filamentous cyanobacteria separating live tissue from white exposed coral skeleton; <i>Agaricia</i> , <i>Meandrina</i> , <i>Mycetophyllia</i> , <i>Colpophyllia</i> , other spp.
Caribbean ciliate infection (CCI)	Linear or annular pigmented band between live tissue and white skeleton	A diffuse black or grey band; “salt-and-pepper” speckled appearance. May form either a discrete, dark band mm-cm thick between recently-exposed skeleton and healthy tissue or diffuse, scattered patches on colonized skeleton; 1-20 cm wide; affects 22 species
Yellow band disease (YBD)	Focal, multifocal lesions that coalesce and form linear to annular bands. Affected tissue is pale yellow.	Begins as a pale yellow, circular patch of tissue surrounded by normal tissue, or as a narrow band at the edge of a colony. Focal, multifocal or annular to linear lesions expand in size slowly (1-20 mm/ month); the leading edge of the band becomes a light pale yellow or lemon color, while tissue first affected gradually darkens prior to dying. Recent tissue loss (white skeleton) is minimal and confined to small (1-2 cm) patches at the margin of affected tissues; primarily affects <i>M.annularis</i> (complex); other faviids
Dark spots disease (DSD)	Round to irregular, focal to multifocal, dark spots, purple to brown in color,	Dark spots grow in size over time, coalesce, and form irregular to annular bands adjacent to or surrounding exposed skeleton. Affected tissue may be associated with a depression of the coral surface. Exposed, underlying skeleton may retain dark color; 1-45 cm diameter; primarily affects <i>Siderastrea</i> , <i>Montastraea</i> , <i>Stephanocoenia</i>
Growth anomalies (GA)	Focal , multifocal and coalescing lesions, circular to irregular shape,	Lesions with a) coenosteal skeleton development between and over normal calices, with corresponding loss of polyps, “Bubbling” of tissue may occur at margin of lesion.; b) abnormally arranged skeletal elements (calices, ridges, valleys), larger or smaller than those of the adjacent colony surface. 1-10 cm diameter or more. All corals


Western Atlantic Coral Diseases



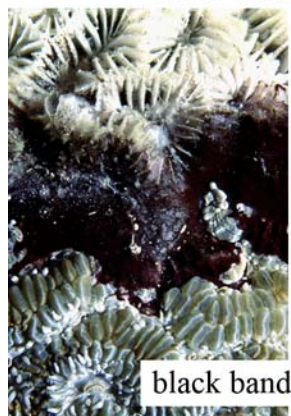
white band disease (WBD)



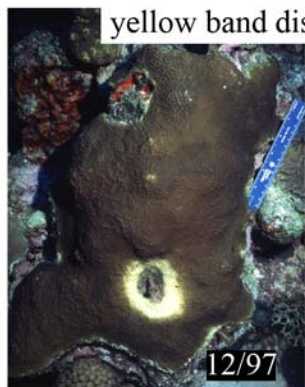
white patch disease (WPD)



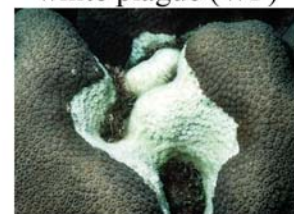
white plague (WP)




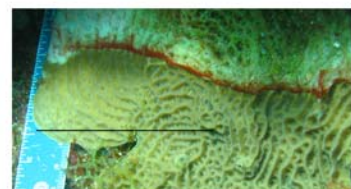
black band disease (BBD)



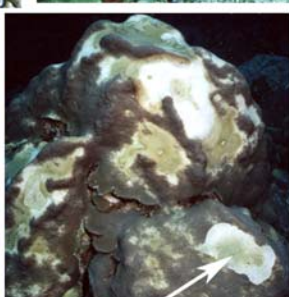
yellow band disease (YBD)



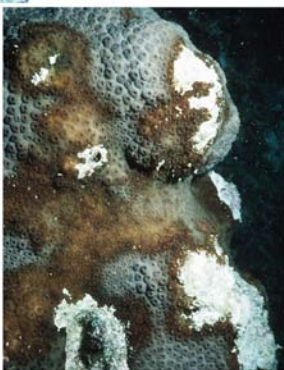red band disease (RBD)




Caribbean ciliate infection (CCI)



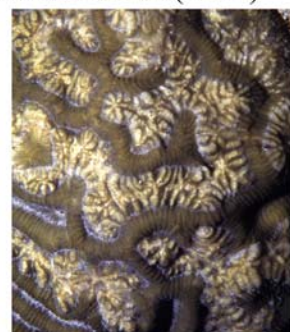bleaching-assoc. mortality



dark spots disease (DSD)



Andrew Bruckner 2009



growth anomaly (GA)